

Hemocytosis, a new disease in cultured shrimp,

Fenneropenaeus indicus

Kakoolaki S.^{1*}; Sharifpour I.¹; Sharifrohani M.¹; Ebrahimzadeh Mousavi H. A.²; Afsharnasab M.¹; Dashtiannasab A.³; Nezamabadi H.¹

Received: November 2012

Accepted: April 2013

Abstract

Certain parasites can cause severe diseases in shrimp. Among these, protozoa are very important. The objective of our study was to describe the signs, prevalence, and intensity of hemocytosis, a new disease in shrimp, *Fenneropenaeus indicus*. The experimental design included three groups, one treatment as infected shrimp or group B and 2 controls with non-infected but exposure to White Spot Syndrom Virus (WSSV) shrimp as group A and non-infected non- exposure to WSSV shrimp as group C in triplicate. The results revealed that Hemocytosis associated with a decrease in hyalinocytes and large-granulocytes (less than 8%) and a considerable increase in semi-granulocytes in group A and B in contrast to group C that Hyalinocyte increased. This infection made the shrimp susceptible to WSSV disease. It is believed that Hemocytosis causes a condition which can result in a rapid mortality among susceptible species, *F. indicus* when exposure to WSSV is occurred.

Keywords: Shrimp, *Fenneropenaeus indicus*, Hemocytosis, Intrahemocyte, Mortality

1- Department of Aquatic Animal Health & Diseases, Iranian Fisheries Research Organization, Tehran, Iran

2-Faculty of Veterinary Medicine, University of Tehran, Tehran, Iran

3-Iranian Shrimp Research Center, Bushehr, Iran

*Corresponding author's email: bsh443@gmail.com

Introduction

In shrimp, the most significant function of the hemolymph cells are the protection of the shrimp versus invading pathogens including viruses, bacteria, fungus and parasites (Tzou et al., 2002; Cerenius and Söderhäll, 2004; Hsieh et al., 2008). The most commonly diseases of the reared shrimp are the invasive viruses and bacteria (Lightner, 2011). Disease prevention has been a priority and shrimp immunology has become a prime branch of research. As reported by Lightner (1992), the need to reduce the lethal and weakening effects of pathogens has stimulated a renewed interest in the defense mechanisms and the immune system of crustaceans. Thus, the number of circulating hemocytes is sometimes used as an indicator of shrimp health status (Perazzolo et al., 2002). Three types of hemocytes have been observed in shrimp *F. indicus* (Kakoolaki et al., 2010; Kakoolaki et al., 2011) but five in *Litopenaeus vannamei* (Muhammad et al., 2012).

Researchers reported mortalities in shrimps due to varied pathogenic species such as *Zoothamnium* spp. in *F. indicus* (Kakoolaki, 1997) Microsporidians, cotton or milk shrimp disease (Lightner, 1985), Cephaline gregarine infection with two genera, *Nematopsis* sp. and *Cephalolobus* sp. in *F. indicus* (Rajendran, 1997). An unusual intraerythrocytic protozoa was reported in *Parablennius cornutus* from South Africa (Davies et al., 2003). *Haemoproteus* spp. were reported in turtles in Australia, Africa and Asia

(Tlford, 2009). Haplosporidian-like protozoan were also reported (Nelson, 2008) in spot and pink shrimps but few and although they are prone to kill a considerable value of pond stock.

In shrimp, the most important role of the circulating hemocytes is the protection of animals against invading microorganisms by participating in recognition, phagocytosis and melanization (Feder, 1999; Fang et al., 2004; FAO, 2010). The most cultured shrimp, in the Americas and Asia have infectious agents as their cause (Damek-Poprawa and Sawicka-Kapusta, 2003). Disease prevention has been a priority and shrimp immunology has become a prime branch of research. As reported by Lightner (1992) the need to reduce the lethal and weakening effects of pathogens is stimulating a renewed interest in the defense mechanisms and the immune system of crustaceans. Thus, hemocytes number sometimes used as an indicator of shrimp health status (Perazzolo et al., 2002). Three types of hemocytes were observed in shrimp *F. indicus* (Kakoolaki et al., 2010; Kakoolaki et al., 2011) but five in *Litopenaeus vannamei* (Golzari et al., 2009). Researchers reported some mortalities in shrimps due to *Zoothamnium* spp. in *F. indicus* (Fontenot et al., 2007) Microsporidians, cotton or milk shrimp disease (Forrester et al., 1974), Cephaline gregarine infection with two genera, *Nematopsis* sp. and *cephalolobus* sp. in *Penaeus indicus* (García et al., 2009). An unusual intraerythrocytic protozoa was

reported in *Parablennius cornutus* from South Africa (Fu et al., 2008). *Haemoproteus* spp. were reported in Turtles in Australia, Africa and Asia (Ganjian et al., 2010). Haplosporidian-like protozoan were also reported (Nelson, 2008) in spot and pink shrimps but few and although they are prone to kill a considerable value of pond stock.

The objective of our study was to express the features of hemocytosis, a new disease made the shrimp susceptible to WSSV disease, prevalence, and intensity of infection. The objective of our study was to describe the signs, prevalence, and intensity of hemocytosis, a new disease in shrimp, *F. indicus*. As it will be discussed, the condition can make the shrimp susceptible to WSSV disease.

Materials and methods

Experimental animals and rearing conditions

Ten-gram three hundred and seventy live shrimps, *F. indicus* were obtained from a private company in southern part of Iran. Shrimp were transferred to Iran Shrimp Research Center located in Bushehr city. One hundred of shrimp were sampled to collect the hemolymph in order to identify the prevalence and intensity of apicomplexan-like microorganism. Remaining shrimp were distributed to 9 aquariums dimensions $50 \times 56 \times 70 \text{ cm}^3$ as 3 groups, 3 replicates each, A & C, 2 control groups in which the group A included healthy shrimp but exposure to WSSV and

group C was known as 2nd control group included infected shrimp with unknown apicomplexan-like microorganisms but not exposure to WSSV. Group B was the treatment and included infected shrimp with unknown apicomplexan-like microorganisms and exposure to WSSV. The shrimp of groups A & B were then exposed to White Spot Syndrome Virus (WSSV) described in previous study of author (Kakoolaki et al., 2011). Group C, as 2nd control shrimp were not exposed to the virus (but with microorganisms). Aquariums were filled with approximately 100 l chlorinated filtered seawater. The water conditions in the aquariums were kept at standard condition with salinity 40 ppt, temperature $28 \pm 0.7 \text{ }^\circ\text{C}$ and dissolved oxygen $5 \pm 0.45 \text{ ppm}$ (Kakoolaki et al., 2010). The shrimp were fed with a commercial imported dry diet twice a day and uneaten feed was removed daily using a siphon.

Hemolymph analysis

Collection of the hemolymph

Ten days after commencing the experiment, 0.2 ml of Hemolymph of all shrimps from each aquarium was withdrawn from the second leg's basement of ventral segments using 1 ml syringes equipped with 26 gauge needles. Each syringe was pre-filled with 0.8 ml Alsever solution as anticoagulant (Kakoolaki et al., 2011; Mohajeri et al., 2011).

DHC, Differentiated Hemocyte Count

A volume of 0.2 ml hemolymphs was withdrawn as mentioned in former subtitle. Each syringe was pre-filled with 0.1 ml fixative. Differential Hemocyte Count (DHC) was analysed by placing a drop of the mixture solution on a glass slide and staining it using the May-Grundwald Giemsa (MGG).

The methods for fixation and staining with *May Grundwald Giemsa (MGG)* of the hemolymph were carried out accordance with Kakoolaki et al. (2011). For each sample, half of the volume was used for the negative staining method at which the cytoplasm contents were stained pale in contrast to the parasite organisms which were stained violet.

Prevalence and intensity of infection

Prevalence of infection was calculated using following formula (OIE, 2006):

$$P = \frac{\text{N of infected shrimps}}{\text{all shrimps in an aquarium}}$$

Where P is prevalence in an aquarium and N is number that given as Mean±SD.

Intensity of infection was formulated as follows (OIE, 2006).

Preparation of WSSV stock solution and inoculation

The infected hemolymph of *Astacus leptodactylus* with the code no. of wssv/irn/1/2011 which had already been prepared at Motamedi lab in Iran (Motamedi Sedeh et al., 2011) was used in the experimental infection study. 50 µl of viral solution (titer of $LC_{50} = 1 \times 10^{5.4}$) was prepared and used. The mixture was stored at -80 °C until use.

Statistical analysis

The independent 2-sample T-test was used to determine the differences (Mean± SD) between the control and treatment groups (A & B) among the Large-Granulocytes, Semi-granulocytes and Hyalinocytes at $\alpha = 0.05$.

Results

According to our results, some Apicomplexan-like parasite were found in the cytoplasm of hemocytes, granular and semi-granular hemocytes but very few in hyaline cells in *F. indicus* in Groups A and C. No infected cells were observed in group B.

The results of some selected parameters, of the unknown infection in the groups were listed in Table 1 given as follows:

Table 1: The prevalence, intensity and DHC of shrimp in various groups

Groups		Prevalence%	Intensity%	DHC %		
				H*	S*	L-G*
Groups	A	0.00	0.00	5	88	7
	B	93.93	95.63±15.95	8	81	11
	C	84.84	91.50±12.80	15	70	15

As Figure 1 shows, the mortality of Group B started at 36 hpi (Hour Post Inoculation) approximately, with half of stocking and completely after 72 hpi meanwhile in group A,

started at 56 hpi and with less than 5% of stocking resulted in whole mortality at 152 hpi. No rather mortality was observed in group C.

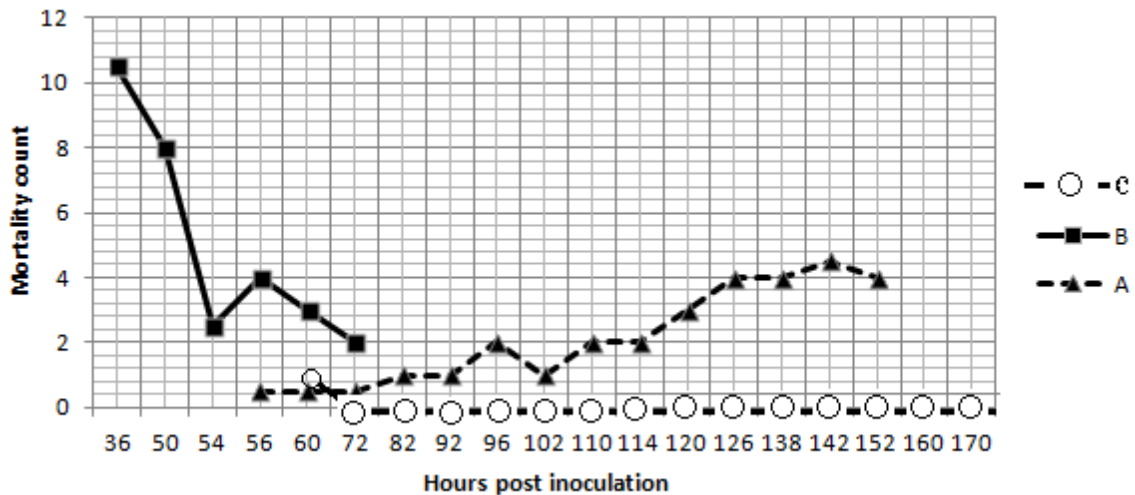


Figure 1: Mortality count among the treatment (B) and controls (A & C) within hpi

Table 2: Comparison between the Control and Treatments group, A & B ($n: 10$)

Criteria	Mean± SD (A;B)	df	P. Value
Large Granulocyte, Length, A and B	13.71± 1.83; 11.45±1.30	8	.005
Large Granulocyte, Width , A and B	7.112±1.75; 6.28±1.10	8	.221
Small Granulocyte, Length , A and B	9.72±1.38; 8.20±0.60	8	.005
Small Granulocyte, Width , A and B	7.42±0.80; 6.86±0.73	8	.120
Hyalinocyte, Length , A and B	6.84±0.29; 7.80±0.46	8	.000
Hyalinocyte, Width , A and B	6.19±0.38; 6.33±0.54	8	.515

Infected semi-granulocytes containing the young trophozoites in comet or ring forms are shown in Figure 2. Ring and double dotted forms of the parasite are seen in Figure 3, e-h where the un-infected cells were obviously clear in comparison to the infected cells. Trophozoites with large vacuole are seen in Figure 4, i-j and late trophozoites in Figure 4, k-l that observed in colder climate. Binary fusions within the parasite are seen in Figure 5, m-n.

Schizont phase was initiated after binary fusion, as can be observed in Figure 5, o. Figure 5, p-r shows the late schizont containing a few merozoites (were seen in warmer water). Figure 6, t, u indicates gametocyte phase. All the mentioned phases of the parasite; ring, trophozoite, schizont and gametocyte-like forms were observed as intrahemocyte microorganisms.

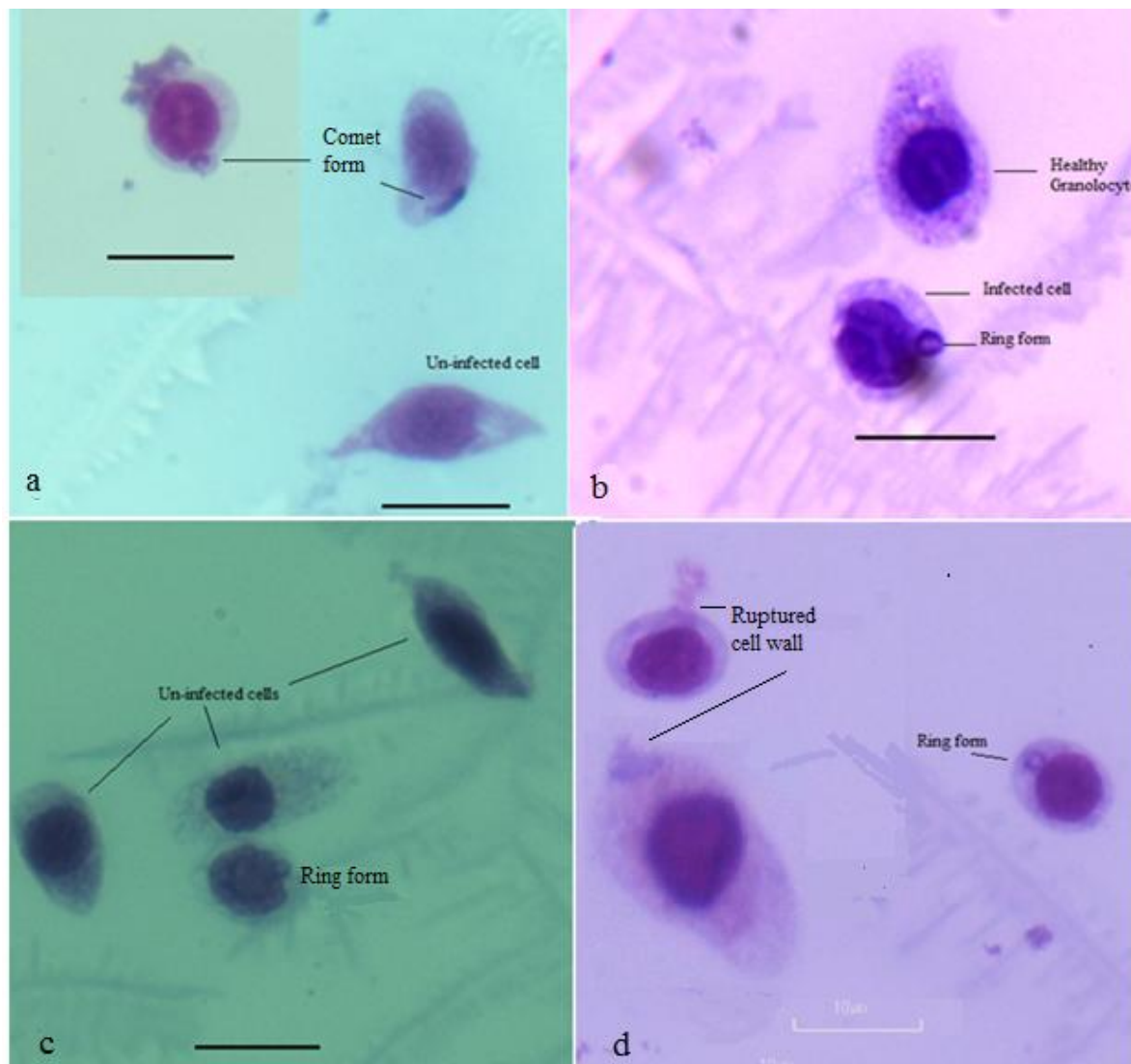


Figure 2: Uninfected and infected shrimp hemocytes with comet and ring forms. Scale bar:10 μ \times 100, May Grunwald –Giemsa staining.

- a, Upper: Infected Semi-Granular cells with comet form, below: Uninfected Granular cell.
- b, Infected Semi-Granular cell shows a ring form below a healthy cell.
- c, (Right cell): Infected Semi-Granular cell shows a ring form below the uninfected cells.
- d, A semi-granular cell (Right) with a ring form and 2 ruptured cell walls

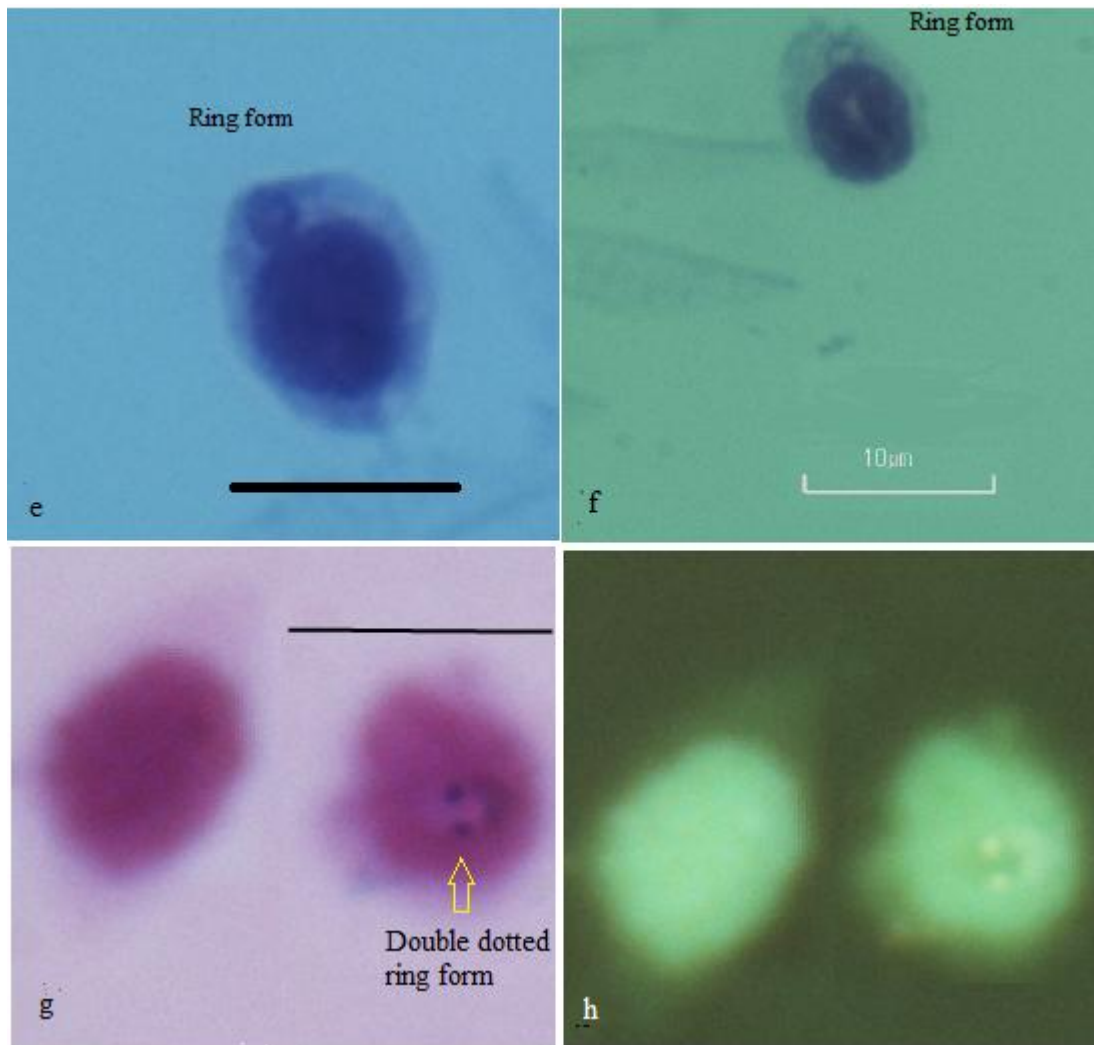


Figure 3: Uninfected and infected shrimp hemocytes × 100, May Grunwald –Giemsa staining.
 e & f, Show infected Semi-Granulocytes with ring forms. g & h, A double dotted uninfected Semi-Granulocyte (h is negative capture of g photo)

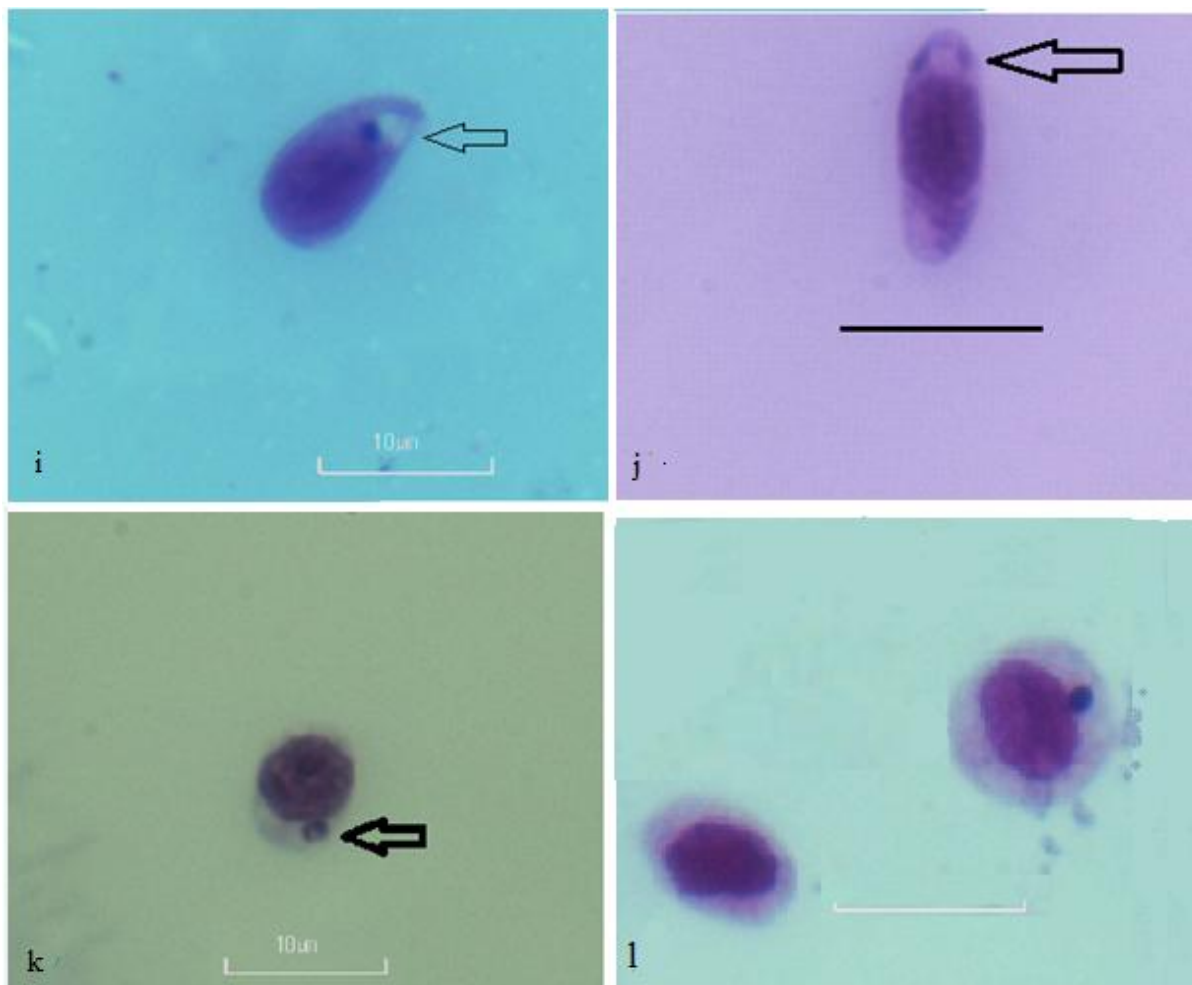


Figure 4: Infected shrimp hemocytes $\times 100$, May Grunwald –Giemsa staining.

i-l show trophozoite stage, i & j show younger trophozoites, k & l show developed trophozoites.

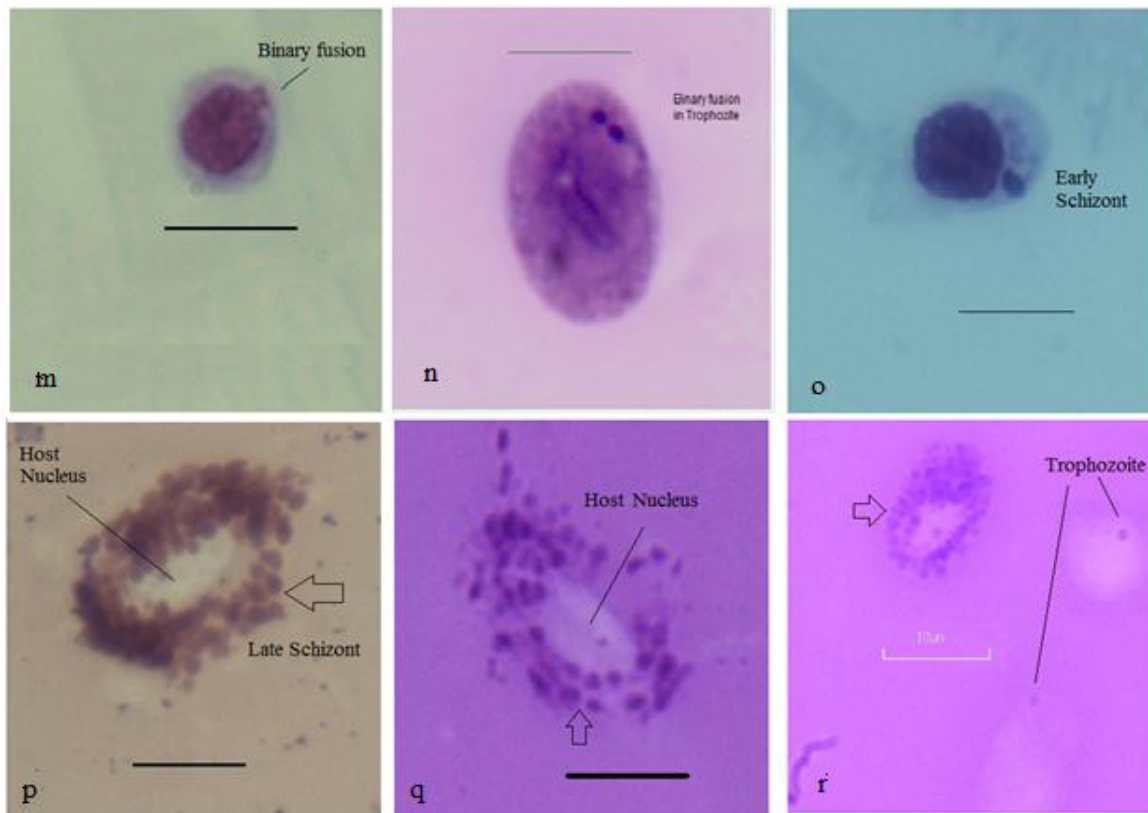


Figure 5: Infected hemocytes at different stages, Scale bar: 10 μ , \times 100, May Grunwald –Giemsa staining.

m & n: Binary fusion in trophozoite; o: Early schizont with 4 nuclei; p-r: Late schizont, Arrows show merozoites surrounded the host nucleus.

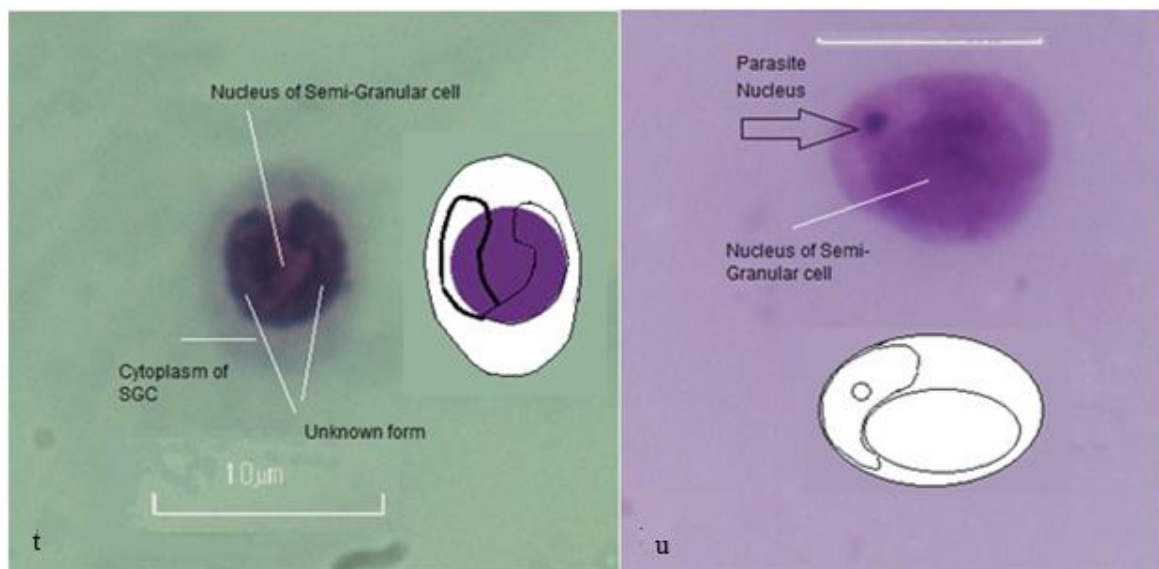


Figure 6: Uninfected and infected shrimp hemocytes (Gametocyte stage). Scale bar: 10 μ , \times 100, May Grunwald –Giemsa staining. t shows two unknown form bodies cover the nucleus of the Semi-Granular cell; u, A large unknown form along with its nucleus.

Discussion

Based on the results given in Table 2, it seems the mean length of the Hyalinocytes, Semi-Granulocytes and Large Granulocytes from the control group A are significantly ($P < .05$) longer than those of group B. Contrarily, no significant differences between the mean width of these two groups among the mentioned hemocytes were observed. It could be due to more pressure of the microorganisms on the poles of the cells and taking more area. On the other hand, these findings lead us to imagine that small size of the infected hemocytes in Hemocytosis could be due to dysfunction and lack of granule production in the cytoplasm because of parasite role.

The percent of the HC and LGC of our finding in comparison to the healthy *F. indicus* (Gopalakrishnan et al., 2010; Kakoolaki et al., 2010) are considerable less but Semi-granulocytes are more than that of healthy cells. Kondo (2003) believed that semi-granulocytes are the immature LGC.

Therefore, lack of appropriate percent of large LGC could be lead to increasing in hemocyte production and the semi-granulocytes were being observed at higher percent in our study. According to our previous study the cytoplasm of the hemocytes are clear and no particles can be observed in it, in contrast to the present study, that showed an intrahemocyte apicomplexan-like organisms seen in the cytoplasm. Using light microscopy, the whole forms

of the intrahemocytic parasite of *F. indicus* resemble those of Apicomplexan-like parasite similar to the finding of Nelson (2000) that showed uni-nucleated stage of the parasite (Haplosporidian-like parasite) with plasmodial forms observed on hemocytes. These forms were visible as early and late trophozoite and schizont-like in colder and warmer weather; respectively conditions indicated that water temperature could be an effective parameter on transitioning stage of the microorganisms.

The prevalence and intensity of the infection were high and it led us to think about a ubiquitous focal point of the infection in the study area. Severe mortality in group B containing the apicomplexan-like parasites can lead to high stress among the shrimp. However, slow progress of the mortality rate in shrimp of group A and no mortality in group C indicates the enhanced immunity levels in these groups, in comparison to that of group B. No mortality was observed in hemocytosis group (Group C) dissimilar to the results of Nelson (Hameed et al., 2000) who showed that when shrimps are maintained in captivity the mortality can be high.

Some researchers reported that invasive viral diseases, such as WSD, TSV, IHHNV, can individually cause rapid mortality (Flegel and Alday-Sanz, 1998; Damek-Poprawa and Sawicka-Kapusta, 2003; Afsharnasab et al., 2007). The results of the present study indicated

that hemocytosis could decline immunity level of shrimp and make them more susceptible to WSSD for higher rate of outbreak of WSD. Apicomplexan-like parasites were housing in cytoplasm of immune cells in hemolymph (Hemocytes), grew and reproduced, consequently. They made cell walls of the hemocytes to be ruptured (Fig. 2d), due to the parasitic reproduction and taking more space of the cytoplasm of infected cells and weakening the immune cells to act as healthy ones (Fig. 5p-r). This was particularly observed in schizont-like phase but sometimes it was seen in ring or comet forms of early trophozoite-like phase, too. According to our results, it revealed that the microorganisms (Figs. 4k & 5o) pushed the host nucleus result in dis-function of DNA. These disorders might result in less efficient immunity of the shrimp hemocytes and thus high mortality rate occurred after exposing the infected shrimp to invasive pathogen, WSSV (Fig. 1). In contrary to the group A, rapid mortality among the shrimp of group B was observed indicating that the infected shrimp are very susceptible to the viral disease, WSSV.

Our results indicate that the prevalence and intensity rates of this Apicomplexan-like microorganism are very high. As, the host cells of the parasite belong to immune system of shrimp (Feder, 1999; Cerenius and Söderhäll, 2004; Hsieh et al., 2008; FAO, 2010). It seems, the parasite could grow in hemocytes, reproduce and

rapture them, weaken the immune system and increasing susceptibility of shrimps to invasive diseases i. e. WSSV. These young parasites were small. According to the Figure 1, the infected cells were not been well grew or developed in comparison with non-infected cells (Fig. 2). Some stages of the intrahemocyte parasites i.e. double dotted and young trophozoite-like forms are very similar to those of *Plasmodium* spp. or other piroplasma protozoa.

According to the results, the amounts of prevalence and intensity of the disease were high, resulted in rapid disperse of disease among the shrimp at risk. It is concluded that Hemocytosis did not cause clinical disease, but it was associated with increasing in the amount and of Semi-granulocyte and Hyalinocyte percents. It results in declining the level of immunity in susceptible species, *Fenneropenaeus indicus* and makes a rapid mortality among them in exposure to WSSV.

Acknowledgments

The authors thank to IFRO for providing financial support for the project.

References

- Afsharnasab, M., Dashtiannasab, A., Yeganeh, V. and Soltani, M., 2007.** [incidence of white spot disease (wsd) in *P. indicus* farms in Bushehr province, Iran]. *Iranian*

Fisheries Scientific Journal, 7, 15-26.

Cerenius, L. and Söderhäll, K., 2004.

The prophenoloxidase-activating system in invertebrates. *Immunological Reviews*, 198 (1), 116-126.

Damek-Poprawa, M. and Sawicka-Kapusta, K., 2003.

Damage to the liver, kidney, and testis with reference to burden of heavy metals in yellow-necked mice from areas around steelworks and zinc smelters in Poland. *Toxicology*, 186 (1-2), 1-10.

Davies, A. J., Reed, C. C. and Smit, N. J., 2003.

An unusual intraerythrocytic parasite of *Parablennius cornutus* from South Africa. *The Journal of Parasitology*, 89 (5), 913-917.

Fang, H.-M., Ge, R. and Sin, Y. M., 2004.

Cloning, characterisation and expression of *Aeromonas hydrophila* major adhesin. *Fish & Shellfish Immunology*, 16 (5), 645-658.

FAO. 2010. The state of world fisheries and aquaculture (sofia),2008. Available:

<http://www.fao.org/fishery/sofia/en> [Accessed 28.10.2010].

Feder, M. E., 1999. Heat-shock proteins, molecular chaperons, and the stress response: Evolutionary and ecological physiology *Annual Review of Physiology*, 61, 243-282.

Flegel, T. W. and Alday-Sanz, V., 1998.

The crisis in asian shrimp aquaculture: Current status and future needs. *Journal of Applied Ichthyology*, 14 (3-4), 269-273.

Fontenot, Q., Bonvillain, C., Kilgen, M. and Boopathy, R., 2007.

Effects of temperature, salinity, and carbon: Nitrogen ratio on sequencing batch reactor treating shrimp aquaculture wastewater. *Bioresour Technol*, 98 (9), 1700-1703.

Forrester, D. J., Hon, L. T., Williams, L. E. and Austin, D. H., 1974.

Blood protozoa of wild turkeys in Florida*. *Journal of Eukaryotic Microbiology*, 21 (4), 494-497.

Fu, L. L., Li, W. F., Du, H. H., Dai, W. and Xu, Z. R., 2008.

Oral vaccination with envelope protein vp28 against white spot syndrome virus in *Procambarus clarkii* using *Bacillus subtilis* as delivery vehicles. *Letters in Applied Microbiology*, 46 (5), 581-586.

Ganjan, A., Wan Maznah, W. O., Yahya, K., Fazli, H., Vahedi, M., Roohi, A. and Farabi, S. M. V., 2010.

Seasonal and regional

distribution of phytoplankton in the southern Caspian Sea. *Iranian Journal of Fisheries Sciences*, 9 (3), 382-401.

García, J. C., Reyes, A., Salazar, M. and Granja, C. B., 2009. Differential gene expression in white spot syndrome virus (wssv)-infected naïve and previously challenged pacific white shrimp *Penaeus (Litopenaeus) vannamei*. *Aquaculture*, 289 (3-4), 253-258.

Golzari, A., Khodabandeh, S. and Seyfabadi, J., 2009. Some biological characteristics of tadpole shrimp, *Triops cancriformis*, from seasonal pools of west Azarbaijan (Iran). *Journal of Agricultural Science and Technology*, 11 (1), 81-90.

Gopalakrishnan, A., Rajkumar, M., Sun, J., Wang, M. and Senthil Kumar, K., 2010. Mud crab, *Scylla tranquebarica* (decapoda: Portunidae), a new host for the white spot Syndrome virus. *Aquaculture Research*, 42,(2), 308-.312.

Hameed, A. S. S., Charles, M. X. and Anilkumar, M., 2000. Tolerance of *Macrobrachium rosenbergii* to white spot syndrome virus. *Aquaculture*, 183, 207-213.

Hsieh, S.-L., Ruan, Y.-H., Li, Y.-C., Hsieh, P.-S., Hu, C.-H. and Kuo,

C.-M., 2008. Immune and physiological responses in pacific white shrimp (*Penaeus vannamei*) to *Vibrio alginolyticus*. *Aquaculture*, 275 (1-4), 335-341.

Kakoolaki, S., 1997. Severe mortality in zoea of cultured *Penaeus semisulcatus* due to *Zoothamnium* sp. *Newsletter of Iranian Fisheries Research Organization*, 18.

Kakoolaki, S., Sharifpour, I., Soltani, M., Ebrahimzadeh Mousavi, H. A., Mirzargar, S. and Rostami, M., 2010. Selected morpho-chemical features of hemocytes in farmed shrimp, *Fenneropenaeus indicus* in iran. *Iranian Journal of Fisheries Sciences*, 9 (2), 219-232.

Kakoolaki, S., Soltani, M., Ebrahimzadeh Mousavi, H. A., Sharifpour, I., Mirzargar, S., Afsharnasab, M. and Motalebi, A. A., 2011. The effect of different salinities on mortality and histopathological changes of spf imported *Litopenaeus vannamei*, experimentally exposed to white spot virus and a new differential hemocyte staining method. *Iranian Journal of Fisheries Sciences*, 10 (3), 447-460.

- Kondo, M., 2003.** Experiments of body defence mechanisms in crustacean. *In: NFU (ed.). Shimonoseki: NFU. Journal of Fisheries Sciences, 10 (2), 254-265.*
- Lightner, D., 1985.** A review of the diseases of cultured penaeid shrimps and prawns with emphasis on recent discoveries and developments. *In: Taki y., primavera j.H. And llobrera j.A. . In: Proceedings of the First International Conference on the Culture of Penaeid Prawns/Shrimps, Iloilo City, Philippines Aquaculture Department, Southeast Asian Fisheries Development Center, 79-103.*
- Lightner, D., 1992.** Shrimp virus diseases: Diagnosis, distribution and management. Proceedings of the special session on shrimp farming, . *In: The World Aquaculture Society, 1992 Baton Rouge: Orlando. 238–253.*
- Lightner, D., 2011.** Virus diseases of farmed shrimp in the western hemisphere (theamericas): A review. *Journal of Invertebrate Pathology, 106, 110-130.*
- Mohajeri, J., Afsharnasab, M., Jalali, B., Kakoolaki, S., Sharifrohani, M. and Haghghi, A., 2011.** Immunological and histopathological changes in *Penaeus semisulcatus* challenged with *Vibrio harveyi*. *Iranian Journal of Fisheries Sciences, 11 (1), 145-155.*
- Motamedi Sedeh, F., Afsharnasab, M., Heidarieh, M., Shafae, S. K., Rajabifar, S., Dashtiannasab, A. and Razavi, M. H., 2011.** Comparison virus titration of the iranian white spot syndrome virus isolate, on crayfish *Astacus leptodactylus* and *Penaeus semisulcatus*. *Iranian Journal of Fisheries Sciences, 11 (1), 145-155.*
- Muhammad, F., Zhang, Z. F., Shao, M. Y., Shi, X. L. and Shafi, M., 2013.** Genesis of hematopoietic tissue and its relation with hemocytes of *Litopenaeus vannamei* (boone, 1931)(crustacea: Decapoda). *Pakistan Veterinary Journal. 33(1), 91-95*
- Nelson, M., 2008.** Haplosporidian-like parasite of shrimp. *Crustacean Protozoa* [Online]. Available: <http://www.adfg.alaska.gov/index.cfm?adfg=beardedseal.main>. [Accessed 12.03.2013].
- OIE. 2006.** *Manual of diagnostic for aquatic animals* [Online]. France: OIE. Available: http://www.oie.int/eng/normes/fmanual/manual2006/A_00047.htm [Accessed 12.11.2010].
- Perazzolo, L. M., Gargioni, R., Ogliari, P. and Barracco, M. A.**

-
- A., 2002.** Evaluation of some hemato-immunological parameters in the shrimp *Farfantepenaeus paulensis* submitted to environmental and physiological stress. *Aquaculture*, 214, 19-33.
- Rajendran, K. V., 1997.** On three protozoan diseases of cultured shrimp. *Indian Journal of Fisheries*, 44 (4), 393-404.
- Tlford, S. R., 2009.** Hemoparasites of the reptilia, color atlas and text, 6000 Broken Sound Parkway NW, Suite 300 Boca Raton, FL 33487-2742: CRC Press Taylor & Francis Group, 394.
- Tzou, P., De Gregorio, E. and Lemaitre, B., 2002.** How drosophila combats microbial infection: A model to study innate immunity and host-pathogen interactions. *Current Opinion in Microbiology*, 5 (1), 102-110.