

Original Article

Evaluation of toxicity and biochemical effects of the Oxadiargyl in Common carp (*Cyprinus carpio* L.)

Hossein Emadi^{*1}, Somayeh Shariatzadeh¹, Shahla Jamili², Ali Mashinchian¹

¹Department of Marine Biology, Faculty of Marine Science and Technology, Science and Research Branch, Islamic Azad University, Tehran, Iran.

²Iranian Fisheries Research Organization, Agriculture Research Education and Extension Organization (AREEO), Tehran, Iran.

Abstract: This study aimed to investigate the effects of sublethal concentrations of oxadiargyl herbicide on growth performance, serum biochemical parameters and liver histology of the common carp, *Cyprinus carpio*, during 30 days exposure period. Carp fingerlings were randomly divided into four duplicate groups. Experimental groups were exposed to the concentration of 0.1, 0.3 and 0.5 ppm of oxadiargyl, while the control group was kept in toxicant free. During the experiment, none of the control fish died. Weight gain and condition factor decreased, while food conversion ratio increased in fish exposed to 0.5 ppm of oxadiargyl. Exposure to oxadiargyl significantly increased serum ALT, AST and ALP, as well as glucose levels, while cholesterol, total protein and albumin were significantly decreased in the exposed fish groups depend on oxadiargyl concentrations and exposure time. Diffuse and focal necrosis mainly as perivascular necrosis fibrosis, increase in size and number of melanomacrophage centers, bile duct hyperplasia, hyperemia and hemorrhage, fatty changes in the hepatocytes, fibrocyte aggregation and focal inflammatory cells were also the histological lesions observed in the liver of exposed fish. These results showed that oxadiargyl is highly toxic to common carp and had negative effects on the growth performance, serum biochemical parameters and the liver tissue of common carp.

Article history:

Received 10 November 2017

Accepted 29 March 2018

Available online 25 April 2018

Keywords:

Carp

Growth performance

Biochemical parameters

Histopathology

Liver

Introduction

Contamination of aquatic environments by runoff and leaching of agricultural pesticides and herbicides poses serious toxicological risks to non-target organisms such as fish and shellfish species (Steinberg et al., 1995; Grung et al., 2015). The exposure of fishes even to low concentrations of herbicides may result in various physiological disorders and cause severe effects on behavior (Steinberg et al., 1995), growth performance (Sweilum, 2006), immune system and susceptibility to infectious diseases (Ahmadvand et al., 2015; Xing et al., 2015), reproduction and endocrine system (Ahmadvand et al., 2016), hematological and biochemical parameters, and histological changes of vital organs (Poleksic and Karan, 1999; Blahova et al., 2014), as well as show genotoxic effects and devastating fish deaths (Bálint et al., 1997; Zanjani et al., 2017).

Oxadiargyl ($C_{15}H_{14}C_{12}N_2O_3$) belonging to the

oxadiazole group, is one of the herbicides extensively applied to control weeds in rice fields in Asia and North Europa as well as in the north of Iran. Oxadiargyl is a broad-leaf herbicide and acts by blocking porphyrin biosynthesis by inhibiting protoporphyrinogen Oxidase (Hwang et al., 2004). Its half-life in soil is 20-30 days, however, its low aqueous solubility led to rapid accumulation and contamination in soil and water bodies (Mahmoudi et al., 2013).

Many experiments investigated the phytotoxic effects of oxadiargyl (Nethra and Jagannath, 2011; Ahmed and Singh-Chauhan, 2015; Monjezi et al., 2015). However, in spite of the genotoxic and hematological effects (Zanjani et al., 2017), as well as the retarding growth (Ajani et al., 2015) induced by the other member of oxadiazole chemical family, oxadiazon in fish, there are a limited data concerning the lethal and sublethal effects of this herbicide on

*Corresponding author: Hossein Emadi
E-mail address: emadihossein@yahoo.com

Table 1. Growth performance in common carp at day 30 after exposure to different concentrations of oxadiargyl (Mean±SE, n=30)

Dose (ppm)	0	0.1	0.3	0.5
Initial weight (g)	19.26±1.26 ^a	18.91±1.39 ^a	19.29±1.47 ^a	19.4±0.92 ^a
Final weight (g)	23.8±1.83 ^a	24.18±1.73 ^a	22.5±2.11 ^a	19.73±0.87 ^b
Weight gain (g)	4.54 ±1.07 ^a	5.27±0.38 ^a	3.21±0.67 ^{ab}	0.33±0.19 ^b
FCR	1.06±0.12 ^a	1.04±0.1 ^a	1.1±0.13 ^a	1.25±0.08 ^b
Initial Size (cm)	10.3±0.25 ^a	9.96±0.05 ^a	10.48±0.43 ^a	10.35±0.43 ^a
Final Size (cm)	10.8±0.23 ^a	10.57±0.45 ^a	10.66±0.65 ^a	10.5±0.65 ^a
Condition Factor	1.9±0.11 ^a	2.04±0.08 ^a	1.86±0.2 ^{ab}	1.7±0.1 ^b

Different letters indicate significant differences at ($P<0.05$) between the experiment groups.

aquatic organism, particularly freshwater fishes.

The common carp, *Cyprinus carpio*, is one of the most important and valuable commercial fish species in Iran that mainly farmed in the north of Iran i.e. Guilan, Mazandaran and Golestan provinces, the area that the oxadiargyl is widely used to control weeds in paddy fields (Mahmoudi et al., 2013). Hence, the present study was aimed to investigate the effect of oxadiargyl on growth performance and serum biochemical parameters in common carp fingerling. Histopathological changes in the liver, the main organ for detoxification was also investigated.

Materials and Methods

Chemicals: Technical grade, oxadiargyl herbicide (3% EC) manufactured by Saveh herbicide Company (Arak, Iran) was used in this study.

Fish and experimental design: Common carp with the mean weight of 19.21 ± 2.3 g and total length of 10.27 ± 0.47 cm were obtained from a local fish farm (Guilan Province, Iran), and acclimated to laboratory conditions in 1000L tanks for two weeks. The fish were randomly selected and introduced into four duplicate 100L tanks (n=30) and exposed to concentrations of 0.1, 0.3 and 0.5 ppm of oxadiargyl. A control with toxicant free water was also maintained. The dechlorinated tap water was used and renewed daily. Physicochemical characteristics were monitored before and after water exchange. The fish were fed (3% of body weight) commercial FFC-Extruded fish food (Faradaneh Company, Iran) twice a day and starved for 24 hrs before sampling.

Growth performance: At the end of the experiment, the body weight and total length of individual fish of control and exposed groups were measured, and the

feed conversion ratio (FCR), weight gain (WG) and condition factor were calculated based on Kane et al. (2016).

Biochemical analysis: At day 30 after sublethal exposure, five fish from each replication were anesthetized with clove powder ($200 \text{ mg}\cdot\text{L}^{-1}$), and blood was collected from caudal vein puncture. The blood was allowed to clot and serum was obtained by centrifugation at $4000\times g$ for 5 min. Then, serum aspartate aminotransferase (AST), alkaline phosphatase (ALP), alanine aminotransferase (ALT), albumin, cholesterol, total protein, and glucose were determined by commercial kits (Parsazmon Co. Iran) according to the manufacturer protocols.

Histopathology: At the end of experiment, three fish from each replication were sampled and the liver tissue was removed for histological examinations. Then the tissues were fixed in 10% NBF, dehydrated and embedded in paraffin, 5 μm sections were prepared and stained with hematoxylin and eosin (H&E) according to Hewitson et al. (2010) and Eagderi et al. (2013), and then examined under a light microscope (Nikon E600).

Statistical analysis: The data were analyzed using the statistical package SPSS20 software (Chicago, IL, USA) by one-way analysis of variance (ANOVA) at $P<0.05$.

Results

Growth performance: The results of growth performance parameters after 30 days sublethal exposure are shown in Table 1. Body weight and total length in the initial control were 19.26 ± 1.26 g and 10.3 ± 0.25 cm, and reached to 23.8 ± 1.83 g and 10.8 ± 0.23 cm, respectively, on day 30. However, the

Table 2. Biochemical parameters in common carp after exposure to different concentrations of oxadiargyl.

Dose (ppm)	0	0.1	0.3	0.5
10 days				
ALT (U L)	26.3±2.1 ^a	25.9±1.3 ^a	28.32±1.56 ^b	32±1 ^c
AST (U L)	143±12.12 ^a	144±11 ^a	178.3±8.7 ^b	236.67±7.6 ^c
ALP (U L)	40.3±3.6 ^a	39.14±2.2 ^a	45.6±1.23 ^b	47±1.2 ^c
Albumin (g dL)	0.96±0.02 ^a	1.01±0.05 ^a	0.98±0.02 ^b	0.78±0.04 ^c
Cholesterol (mg dL)	256±2 ^a	249.67±3.06 ^a	216.67±5.86 ^b	166.67±2.08 ^c
TP (g dL)	2.74±0.1 ^a	2.78±0.21 ^a	2.2±0.14 ^b	2.06±0.12 ^b
Glucose (mg dL)	59.33±7.02 ^a	62.67±2.08 ^a	74±1 ^b	81.67±0.58 ^c
20 days				
ALT (U L)	25.8±1.2 ^a	26.09±1.4 ^a	30.1±1.3 ^b	33.8±1.3 ^c
AST (U L)	141±2.2 ^a	141±9.7 ^a	181.43±5.01 ^b	251.61±4.9 ^c
ALP (U L)	39.8±2.12 ^a	38.9±3.2 ^a	44.67±1.53 ^b	46±3 ^c
Albumin (g dL)	0.99±0.02 ^a	0.95±0.03 ^a	0.86±0.02 ^b	0.69±0.02 ^c
Cholesterol (mg dL)	259±5 ^a	241.61±3.06 ^a	191.67±4.31 ^b	129.67±5.86 ^c
TP (g dL)	2.71±0.01 ^a	2.68±0.24 ^a	2.15±0.1 ^b	1.98±0.03 ^b
Glucose (mg dL)	60.12±4.01 ^a	67.33±2.08 ^{ab}	74±1 ^b	106.34±0.51 ^c
30 days				
ALT (U L)	25.33±2.52 ^a	24.19±1.53 ^a	30.33±1.53 ^b	36±0.8 ^c
AST (U L)	140±12.12 ^a	141±14.8 ^a	187.33±10.07 ^b	267.67±8.96 ^c
ALP (U L)	39.33±3.06 ^a	38.17±2.52 ^a	45.07±2.57 ^b	49±2.8 ^c
Albumin (g dL)	1.03±0.02 ^a	0.94±0.05 ^a	0.75±0.01 ^c	0.67±0.02 ^d
Cholesterol (mg dL)	257±6 ^a	239.67±3.05 ^a	198.67±5.86 ^b	157.66±2.1 ^c
TP (g dL)	2.72±0.02 ^a	2.63±0.24 ^a	2.06±0.12 ^b	1.95±0.02 ^b
Glucose (mg dL)	59.29±5.32 ^a	66.35±3.04 ^a	78±1 ^b	96±1 ^c

Different letters indicate significant differences between the groups at ($P<0.05$).

increase of the weight and length were occurred in the control fish, they were inhibited in the treatments. A significant decrease in weight gain and condition factor, and increased food conversion ratio (FCR) were observed in fish exposed to 0.5 ppm of oxadiargyl ($P<0.05$).

Biochemical parameters: The results of serum biochemical parameters are presented in Table 2. Exposure to oxadiargyl significantly increased serum ALP, AST and ALT, as well as glucose levels, while cholesterol, total protein and albumin were significantly decreased in the exposed fish groups depend on oxadiargyl concentrations and exposure time ($P<0.05$). However, no significant changes in the examined serum biochemical parameters of the fish exposed to 0.1 mg/l of oxadiargyl were observed.

Liver histopathology: The histological details of the carp liver (hepatopancreas) tissue is shown in the Figure 1A. Diffuse and focal necrosis mainly as perivascular necrosis/fibrosis, hyperemia and hemorrhage, fatty changes in the hepatocytes, focal inflammatory cells and fibrocyte aggregation were the

histological lesions in the liver of exposed fish. Sever bile duct hyperplasia and increase in size and number of melanomacrophage centers depend on oxadiargyl concentration were also observed (Fig. 1B, 1D).

Discussion

Oxadiargyl is the main herbicide, extensively applied to control weeds of the rice fields in the Southern Caspian Sea basin (Mahmoudi et al., 2013). The present work studied the toxicity effects of oxadiargyl on different physiological parameters of common carp. Based on the results, histopathologically, oxadiargyl induced mild to severe alternations in liver of common carp depend on herbicide concentrations which may be a result of increasing cell activities, and is in agreement with previous studies reporting different histopathological changes in fish following exposure to herbicides (Ahmadivand et al., 2014; Poleksic and Karan, 1999; Blahova et al., 2014). Moreover, the observed changes in size and number of melanomacrophage centers (MMCs) in liver tissue depend on the herbicide concentration further

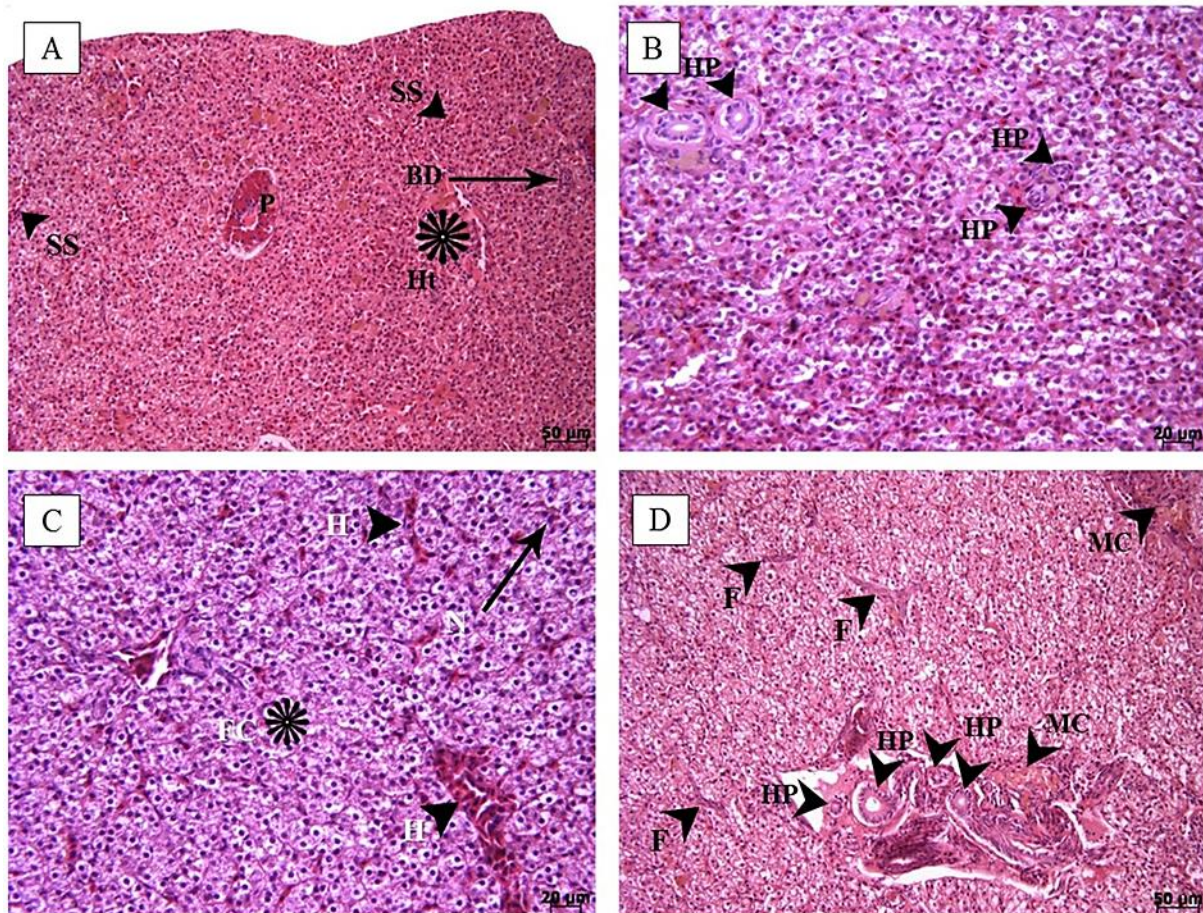


Figure 1. Histopathological changes of the liver tissue of the common carp after 30 days sublethal exposure to oxadiargyl. (A) Liver tissue of control fish, (B) fish exposed to 0.1 ppm, (C) 0.3 ppm, and (D) 0.5 ppm of oxadiargyl; P: Pancreas, Ht: hepatocytes, SS: sinusoidal spaces, FC: Fatty changes, F: fibrosis, MC: melano-macrophage centers, N: necrosis, H: hyperemia, HP: hyperplasia.

confirmed that MMCs can be considered as a biomarker of environmental stress such as pesticides (Ribeiro et al., 2011). The toxic effects of pesticides on hepatic cells may result in the body metabolic alteration as well (Wolf and Wheeler, 2018).

A significant change in serum biochemical parameters, including total protein, albumin, glucose, cholesterol as well as in serum ALP, AST and ALT levels were observed over a 30-day period and the higher concentration of herbicide caused more effects, which is in agreement with the findings of Saravanan et al. (2017), evaluating the acute toxicity effects of oxadiazon on carp. Decrease of total protein and albumin might have been resulted from the impaired protein synthesis due to hepatic dysfunction and immunosuppressive effect of the herbicide (Nayak et al., 2004; Gokcimen et al., 2007). Moreover, change in glucose and cholesterol levels indicate the

metabolic alteration in fish energy sources, especially carbohydrate metabolism due to liver dysfunction (Barton, 2002). Also, the observed increase in serum ALP, ALT and AST activity may be related to tissue damage resulting in the amino acid and protein metabolism disruption.

Detrimental histopathological and biochemical effects can have a negative effect on the growth performance of reared fish and can lead to a decrease in growth and economic losses. Here, the growth performance of exposed fish was inhibited, which is in agreement with previous reports studying growth parameters of fish (Ajani et al., 2015), as well as the rodents and dog (Richert et al., 1996) following exposure to oxadiazole group. Similarly, Ajani et al. (2015) found a significant decrease in the growth and feed intake and utilization of African Catfish (*Clarias gariepinus*) exposed to 0.008 mL.L⁻¹ and 0.02 mL.L⁻¹ of

oxadiazon, the other member of oxadiazole group. Also, Saravanan et al. (2017) assessed the acute toxicity effects of 0.5, 5 and 50 $\mu\text{g.L}^{-1}$ oxadiazon on carp for 96 hrs, and reported that this herbicide negatively affected the hematological and biochemical parameters of the fish. However, regarding the effects of oxadiargyl on fish growth no data was found. Therefore, the growth inhibition by exposure to oxadiargyl in the current study may be due to the reduced fish appetite, dysfunction in metabolism process and waste of energy to overcome the stress caused by the herbicide (Abdul-Farah et al., 2004).

In conclusion, the results showed that oxadiargyl has a significant negative effect on growth performance and induces significant biochemical and histopathological alterations in the liver of common carp, and it is suggested that this herbicide is highly toxic for *C. carpio*. However, further studies need to find out its toxic effects on the other physiological parameters of the fish.

Acknowledgments

The authors would like to thank M. Ahmadpoor for assisting with the histological sections.

References

- Abdul-Farah M., Ateeq B., Ali M.N., Ahmad W. (2004). Studies on lethal concentrations and toxicity stress of some xenobiotics on aquatic organisms. *Chemosphere*, 55: 257-265.
- Ahmadivand S., Farahmand H., Mirvaghefi A., Eagderi S., Shokrpour S., Rahmati-Holasoo H. (2014). Histopathological and haematological response of male rainbow trout (*Oncorhynchus mykiss*) subjected to butachlor. *Veterinari Medicina*, 59: 433-439.
- Ahmadivand S., Farahmand H., Mirvaghefi A., Eagderi S., Zargar A. (2015). Effects of (anti) androgenic endocrine disruptors (DEHP and Butachlor) on immunoglobulin M (IgM) and leukocytes counts of male rainbow trout (*Oncorhynchus mykiss*). *Bulletin of Environmental Contamination and Toxicology*, 94: 695-700.
- Ahmadivand S., Farahmand H., Teimoori-Toolabi L., Mirvaghefi A., Eagderi S., Geerinckx T., Shokrpour S., Rahmati-Holasoo H. (2016). Boule gene expression underpins the meiotic arrest in spermatogenesis in male rainbow trout (*Oncorhynchus mykiss*) exposed to DEHP and butachlor. *General and Comparative Endocrinology*, 225: 235-241.
- Ahmed S., Singh-Chauhan B. (2015). Efficacy and phytotoxicity of different rates of oxadiargyl and pendimethalin in dry-seeded rice (*Oryza sativa L.*) in Bangladesh. *Crop Protection*, 72: 169-174.
- Ajani F., Oluyinka-Ajiboye A., Oluwatosin-Oyelowo O. (2015). Effects of Oxadiazon on Nutrient Utilization and Growth of African Catfish (*Clarias gariepinus*). *American Journal of Agricultural Science*, 2: 121-125.
- Bálint T., Ferenczy J., Kátai F., Kiss I., Kráczler L., Kufcsák O., Láng G., Polyhos C., Szabó I., Szegletes T., Nemcsók J. (1997). Similarities and differences between the massive eel (*Anguilla anguilla L.*) devastations that occurred in Lake Balaton in 1991 and 1995. *Ecotoxicology and Environmental Safety*, 37: 17-23.
- Barton B.A. (2002). Stress in fishes: a diversity of responses with particular reference to changes in circulating corticosteroids. *Integrative and Comparative Biology*, 42: 517-25.
- Blahova J., Modra H., Sevcikova M., Marsalek P., Zelnickova L., Skoric M., Svobodova Z. (2014). Evaluation of biochemical, haematological, and histopathological responses and recovery ability of common carp (*Cyprinus carpio L.*) after acute exposure to atrazine herbicide. *BioMed Research International*, 98094: 1-8.
- Eagderi S., Mojazi Amiri B., Adriaens D. (2013). Description of the ovarian follicle maturation of the migratory adult female bulatmai barbel (*Luciobarbus capito*, Gúldenstädt 1772) in captivity. *Iranian Journal of Fisheries Sciences*, 12(3): 550-560.
- Gokcimen A., Gulle K., Demirin H., Bayram D., Kocak A., Altuntas I. (2007). Effects of diazinon at different doses on rat liver and pancreas tissues. *Pesticide Biochemistry and Physiology*, 87: 103-108.
- Grung M., Lin Y., Zhang H., Steen A.O., Huang J., Zhang G., Larssen T. (2015). Pesticide levels and environmental risk in aquatic environments in China: A review. *Environment International*, 81: 87-97
- Hewitson T.D., Wigg B., Becker G.J. (2010). Tissue preparation for histochemistry: fixation, embedding and antigen retrieval for light microscopy. In: T.D., Hewitson, I.A. Darby (Eds.), *Histology Protocols*. Humana Press, New York. pp: 3-18.

- Hwang I. T., Hong K.S., Choi J.S., Kim H.R., Jeon D.J., Cho K.Y. (2004). Protoporphyrinogen ix-oxidizing activities involved in the mode of action of a new compound N-[4-Chloro-2-Fluoro-5-{3-(2-Fluorophenyl)-5-Methyl-4,5-Dihydroisoxazol-5-Yl-Methoxy}-Phenyl]-3,4,5,6-Tetrahydrophthalimide. *Pesticide Biochemistry and Physiology*, 80: 123-130.
- Kane A.M., Soltani M, Ebrahimzahe-Mousavi H.A, Pakzad K. (2016). Influence of probiotic, *Lactobacillus plantarum* on serum biochemical and immune parameters in vaccinated rainbow trout (*Oncorhynchus mykiss*) against streptococcosis/lactococcosis. *International Journal of Aquatic Biology*, 4: 285-294.
- Mahmoudi M., Rahnemaie R., Eshaghi A., Malakouti M.J. (2013). Kinetics of degradation and adsorption-desorption isotherms of thiobencarb and oxadiargyl in calcareous paddy fields. *Chemosphere*, 91: 1009-1017.
- Monjezi N., Razmjo J., Karimmojeni H. (2015). Valerian (*Valeriana officinalis* L.) tolerance to some post-emergence herbicides. *Journal of Plant Protection Research*, 55: 415-420.
- Nayak A.K., Das B.K., Kohli M.P.S., Mukherjee S.C. (2004). The immunosuppressive effect of alpha-permethrin on Indian major carp, rohu (*Labeo rohita* Ham.). *Fish and Shellfish Immunology*, 16: 41-50.
- Nethra N.S., Jagannath S. (2011). Phytotoxic effect of oxadiargyl on germination and early growth of sunflower (*Helianthus annuus* L.) and maize (*Zea mays* L.). *Archives of Phytopathology and Plant Protection*, 44: 1901-1907.
- Poleksic V., Karan V. (1999). Effects of trifluralin on carp: biochemical and histological evaluation. *Ecotoxicology and Environmental Safety*, 43: 213-221.
- Ribeiro H.J., Procópio M.S., Gomes J.M.M., Vieira F.O., Russo R.C., Balzuweit K., Chiarini-Garcia H., Santana-Castro A.C., Rizzo E., Corrêa-Jr J.D. (2011). Functional dissimilarity of melanomacrophage centres in the liver and spleen from females of the teleost fish *Prochilodus argenteus*. *Cell Tissue Research*, 346: 417-425.
- Richert L., Price S., Chesne C., Maita K., Carmichael N. (1996). Comparison of the induction of hepatic peroxisome proliferation by the herbicide oxadiazon in vivo in rats, mice, and dogs and in vitro in rat and human hepatocytes. *Toxicology and Applied Pharmacology*, 141: 35-43.
- Saravanan M., Kim J.Y., Hur K.J., Ramesh M., Hur J-H. (2017). Responses of the freshwater fish *Cyprinus carpio* exposed to different concentrations of butachlor and oxadiazon. *Biocatalysis and Agricultural Biotechnology*, 11: 275-281.
- Steinberg C.E.W., Lorenz R., Spieser O.H. (1995). Effects of atrazine on swimming behavior of zebrafish, *Brachydanio rerio*. *Water Research*, 29: 981-985.
- Sweilum M.A. (2006). Effect of sublethal toxicity of some pesticides on growth parameters, haematological properties and total production of Nile tilapia (*Oreochromis niloticus* L.) and water quality of ponds. *Aquaculture Research*, 37: 1079-1089.
- Wolf J.C., Wheeler J.R. (2018). A critical review of histopathological findings associated with endocrine and non-endocrine hepatic toxicity in fish models. *Aquatic Toxicology*, 197: 60-78.
- Xing H., Liu T., Zhang Z., Wang X., Xu S. (2015). Acute and subchronic toxic effects of atrazine and chlorpyrifos on common carp (*Cyprinus carpio* L.): Immunotoxicity assessments. *Fish and Shellfish Immunology*, 45: 327-333.
- Zanjani S.A., Emadi H., Jamili S., Mashinchian A. (2017). DNA damage and hematological changes in Common carp (*Cyprinus carpio*) exposed to oxadiazon. *International Journal of Aquatic Biology*, 5: 387-392.

چکیده فارسی

بررسی اثرات علف‌کش اکسادیازثیل بر پارامترهای رشد و بیوشیمیایی در ماهی کپور معمولی (*Cyprinus carpio*)

حسین عمادی^{۱*}، سمیه شریعت‌زاده^۱، شهلا جمیلی^۲، علی ماشینچیان^۱

^۱گروه بیولوژی دریا، واحد علوم تحقیقات، دانشگاه آزاد اسلامی، تهران، ایران.
^۲موسسه تحقیقات علوم شیلاتی کشور، سازمان تحقیقات، آموزش و ترویج کشاورزی، تهران، ایران.

چکیده:

این مطالعه با هدف بررسی اثرات علف‌کش اکسادیازثیل بر پارامترهای رشد و بیوشیمیایی و همچنین میزان آسیب بافتی کبد در ماهی کپور معمولی، *Cyprinus carpio*، انجام شد. برای این منظور تعداد ۱۲۰ عدد ماهی کپور (میانگین وزنی $19/27 \pm 2/3$ گرم در چهار گروه هر کدام با دو تکرار و تراکم ۱۵ ماهی در تانک‌های ۱۰۰ لیتری به مدت ۳۰ روز در معرض غلظت‌های ۰، ۰/۱، ۰/۳ و ۰/۵ میلی‌گرم در لیتر سم اکسادیازثیل قرار گرفتند. در انتهای دوره آزمایش بیومتری انجام و از ماهیان نمونه بافت کبد و خون تهیه و پارامترهای رشد بیوشیمیایی سرم بین گروه‌ها مقایسه شد. تغییر معنی‌داری در میزان میانگین افزایش وزن، ضریب تبدیل غذایی و فاکتور وضعیت گروه‌های تیمار در مقایسه با گروه کنترل مشاهده گردید ($P < 0/05$). به‌علاوه در گروه‌های تیمار اکسادیازثیل میزان گلوکز و همچنین آنزیم کبدی ALT، AST و ALP سرم افزایش معنی‌داری مشاهده شد، در حالی که کلسترول، پروتئین کل و آلبومین این گروه‌ها کاهش معنی‌داری نشان دادند ($P < 0/05$). هایپرپلازی مجاری صفراوی و تشکیل بافت فیبروز حاوی رشته‌های کلاژن و فیبروسیت‌ها، تغییر چربی در تعداد زیادی از هیاتوسیت‌ها و نفوذ سلول‌های التهابی تک‌هسته‌ای و همچنین افزایش متوسطی در اندازه و تعداد مراکز ملانوماکروفاژ در بافت کبد در پایان دوره ۳۰ روزه با سم مذکور مشاهده شد. بر اساس نتایج این مطالعه اکسادیازثیل برای ماهی کپور بسیار سمی بوده و اثرات شدیدی بر اندام کبد، میزان رشد و پارامترهای بیوشیمیایی این ماهی می‌گذارد. کلمات کلیدی: کپور، پارامترهای رشد، پارامترهای بیوشیمیایی، آسیب شناسی، کبد.